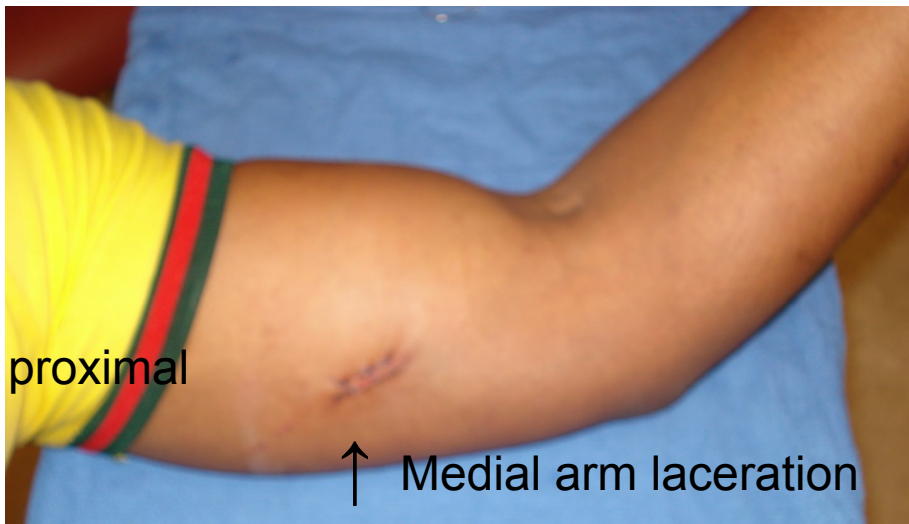
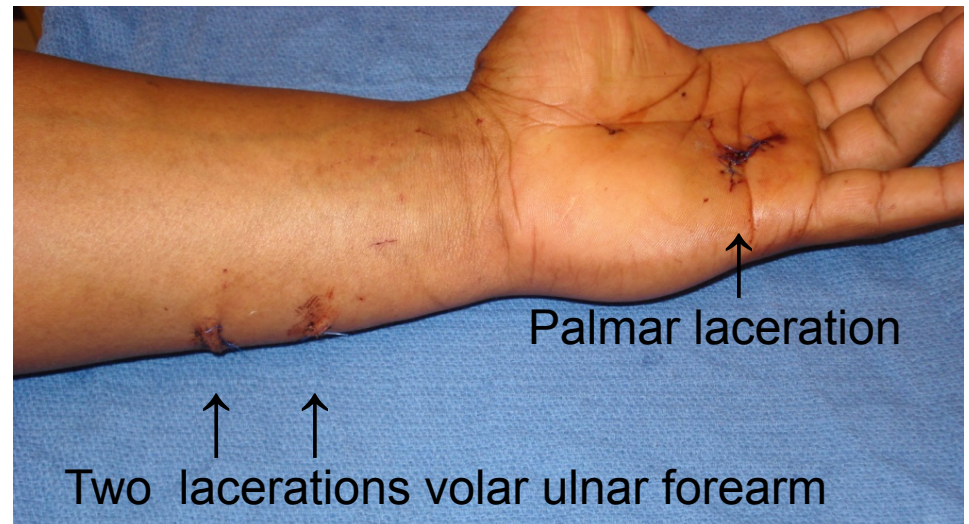


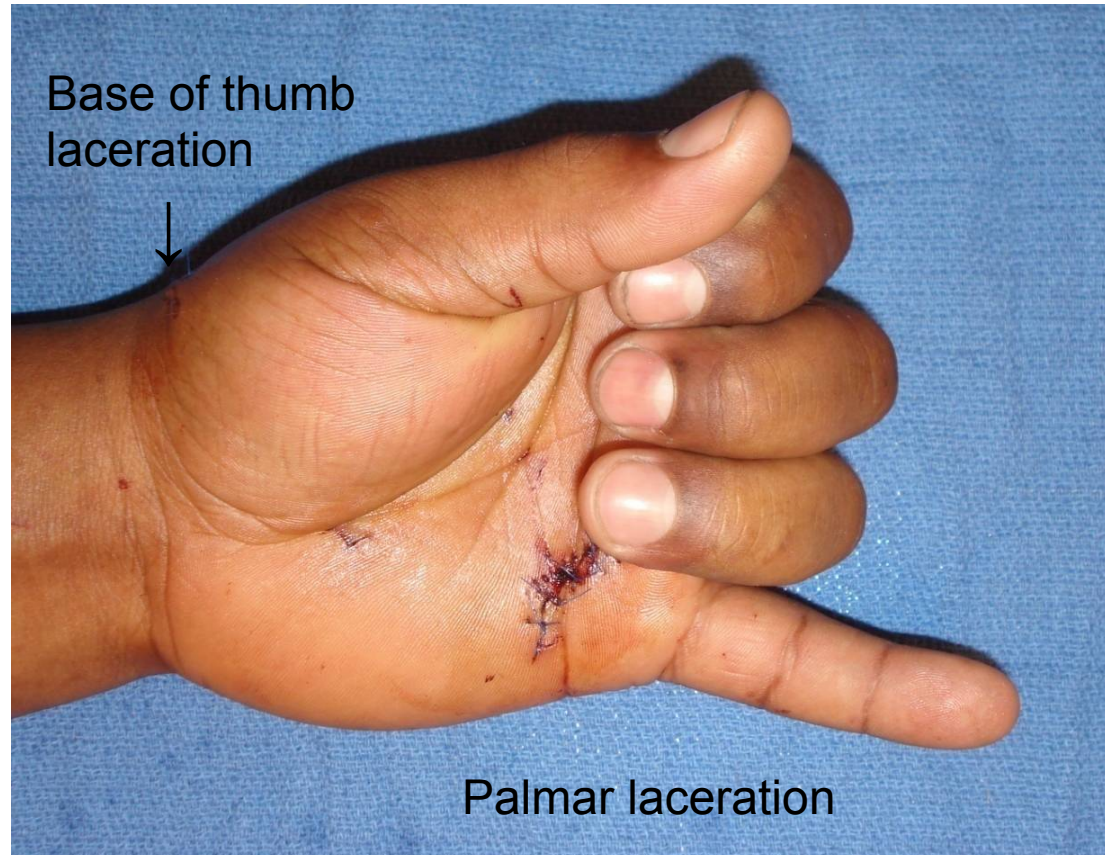
In-office initial visit: 24 y/o male presented after being cut by glass and not being able to close his hand. He was diagnosed with a flexor tendon injury.



In-office initial visit

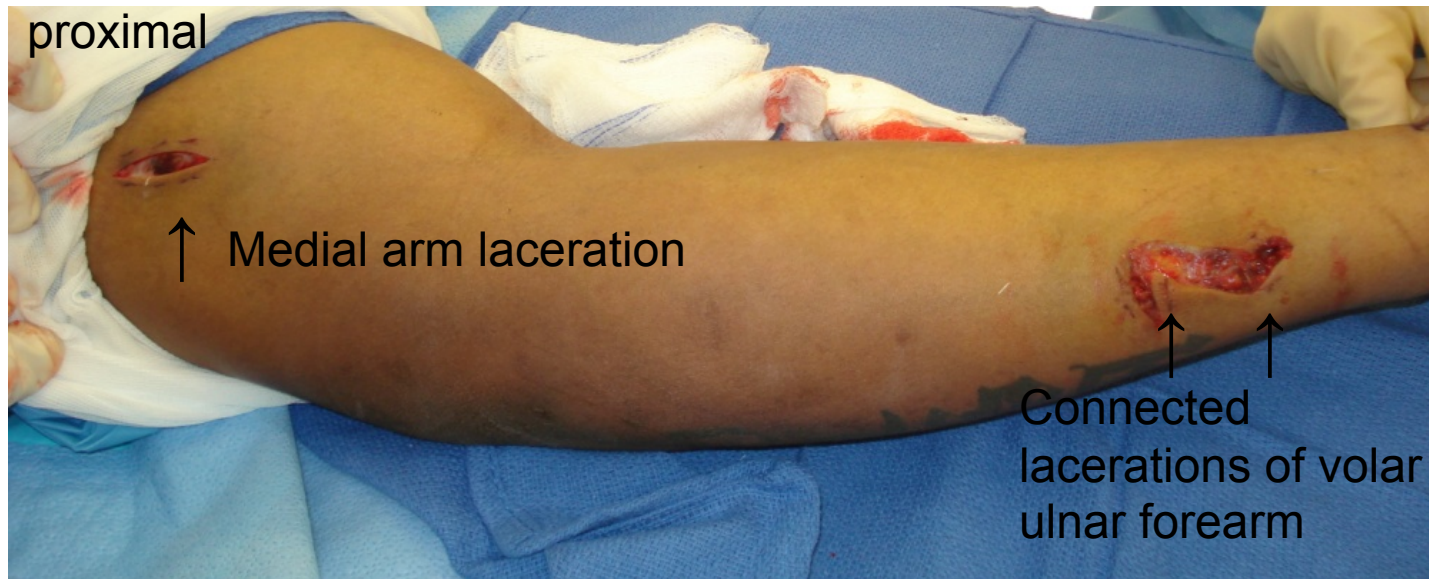


In-office initial visit

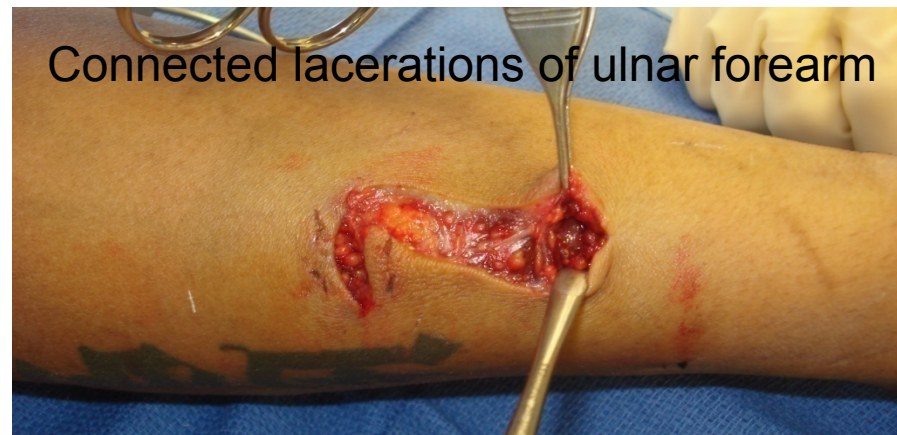

In-office initial visit: The patient is unable to close his small finger.

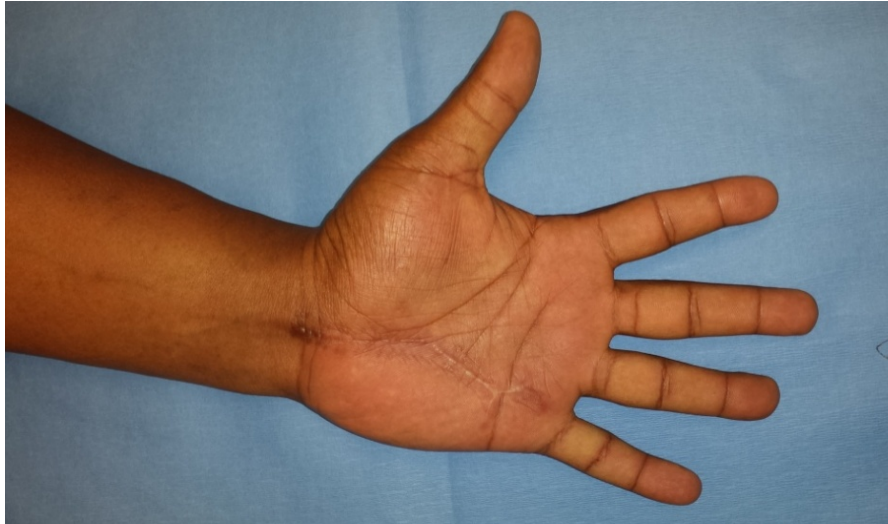Intra-operative: Exploration of the wounds and repair of the cut flexor tendons



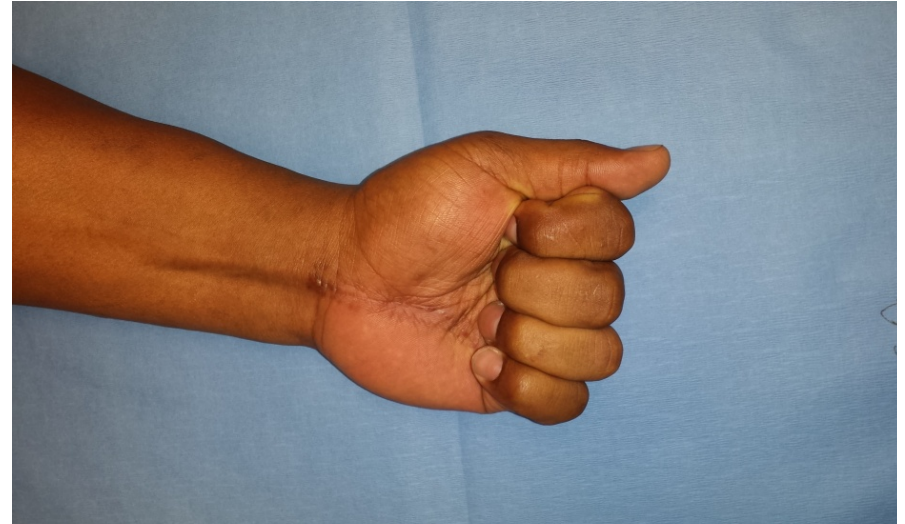Intra-operative



Intra-operative



Postoperative after therapy and rehab,
regained full function.



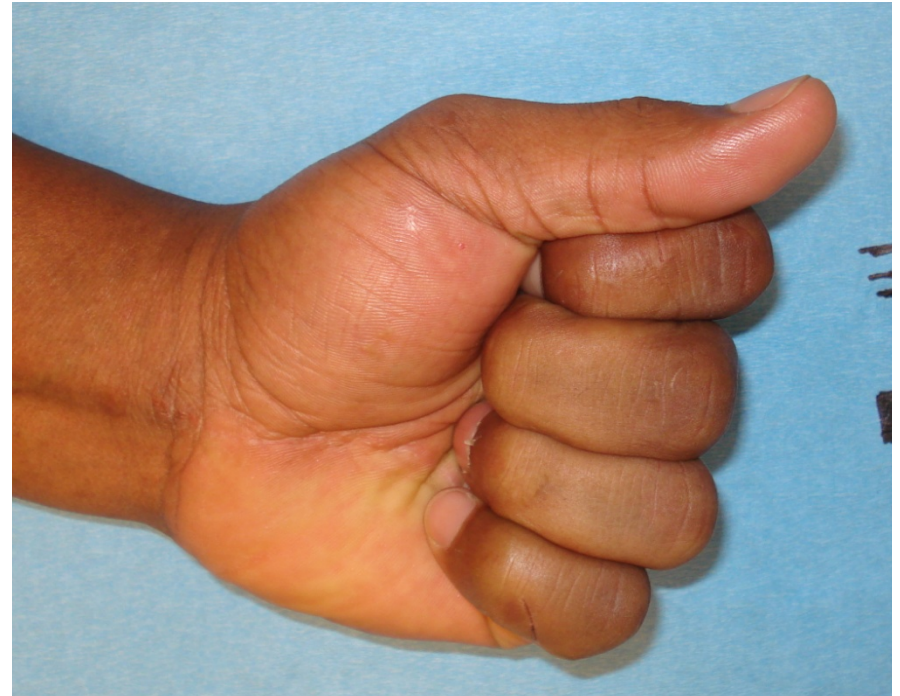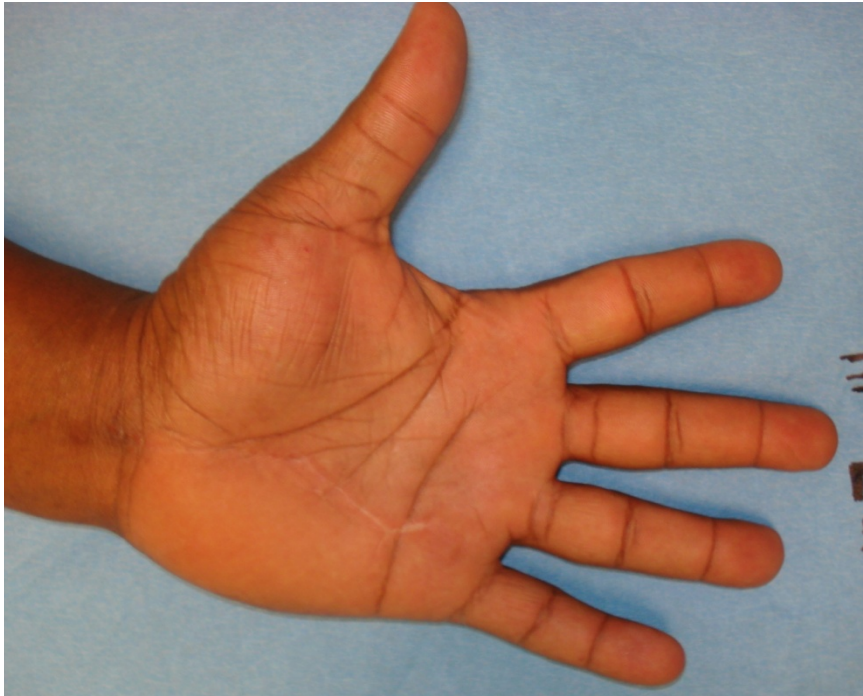
Postoperative after therapy and
rehab, regained full function.

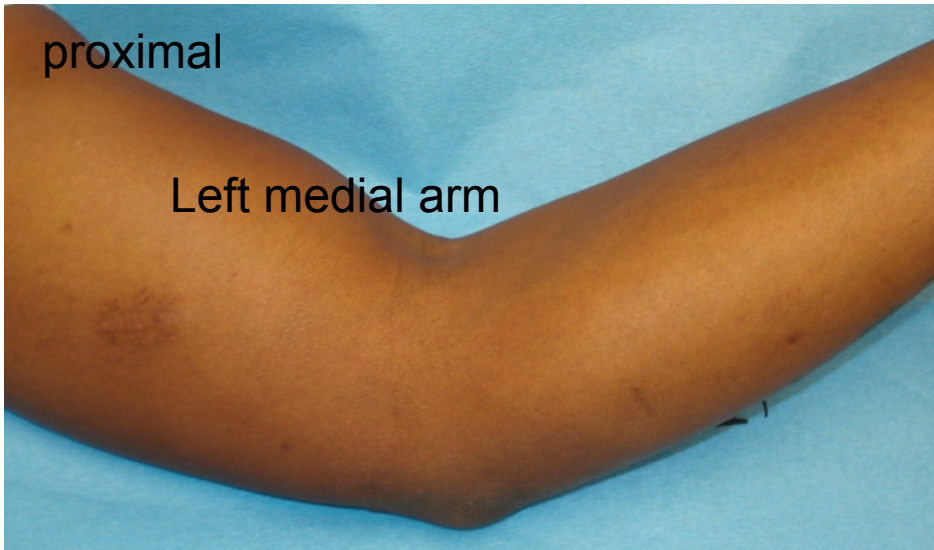


SFHS

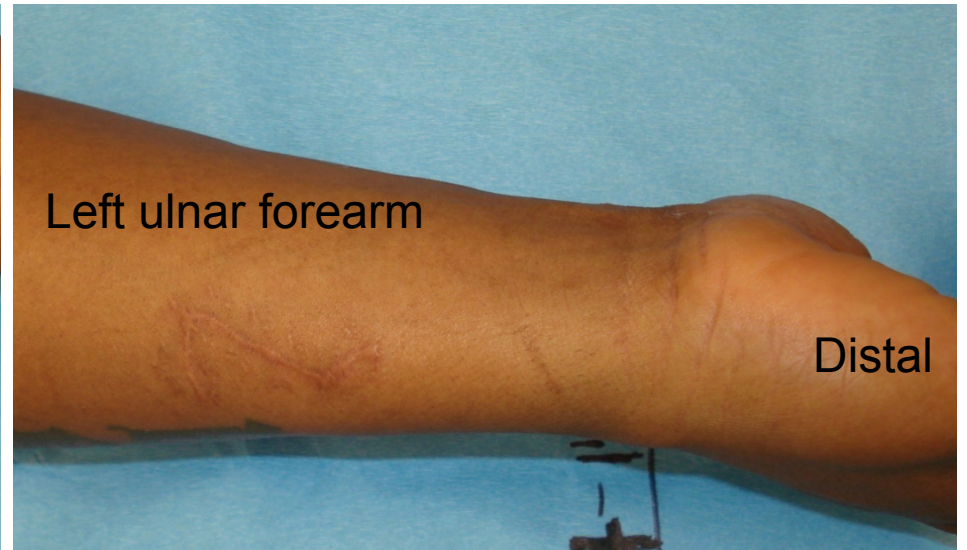South Florida Hand Surgery

4308 Alton Road #940 Miami Beach, FL 33140





Post-operative



Post-operative